

# **INSTRUMENTS COMPILED**

---

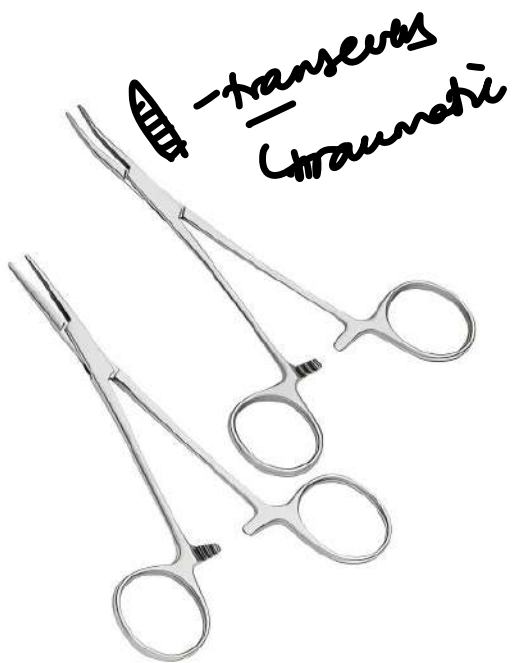# **INTEGRATED MODULE**

# SURGERY

---

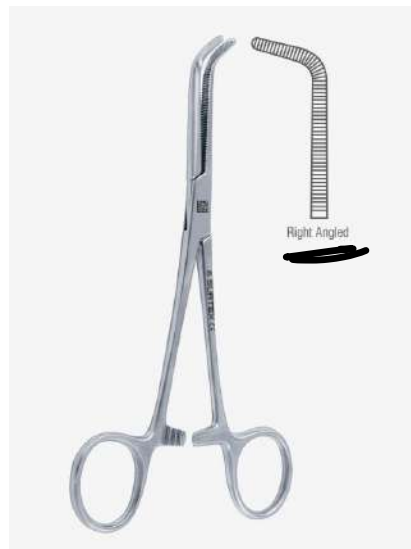SCISSOR VS FORCEPS: screw jt vs Box jt

 - atraumatic ANTOCLAVE



- transect  
traumatic

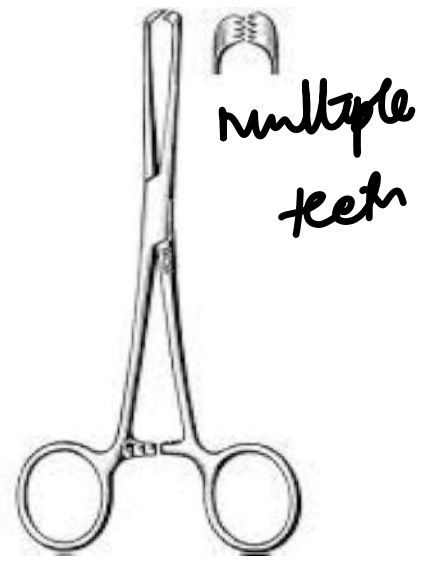Kelly's hemostatic artery forceps



Mixer's right L forceps  
↓  
hemostatic



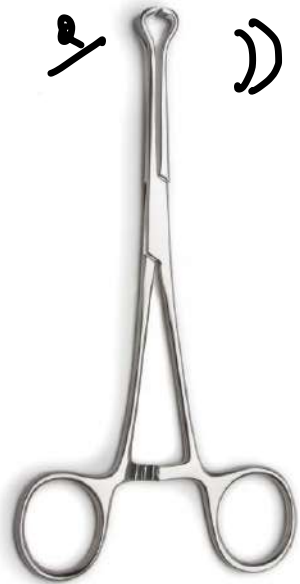Kocher's forceps  
↓  
vessels/pedicles  
ARM



Allis forceps  
↓  
- fascia/rectus  
- episiotomy  
- uterine incision



Green Armytage forceps  
↓  
uterine incision



Babcock forceps

↓

tubular

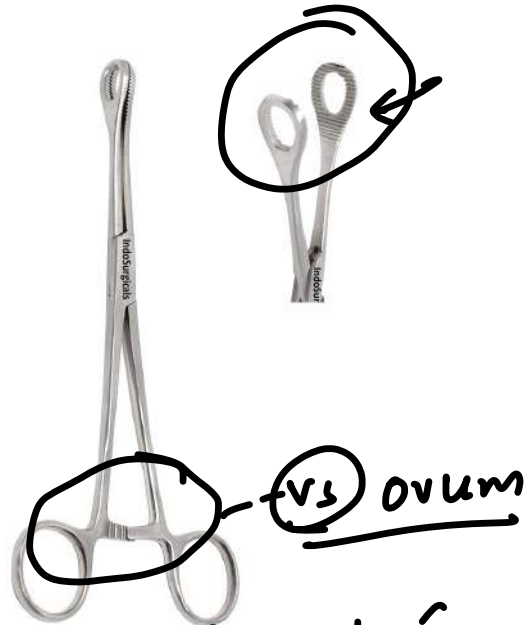
- intestine

- FT

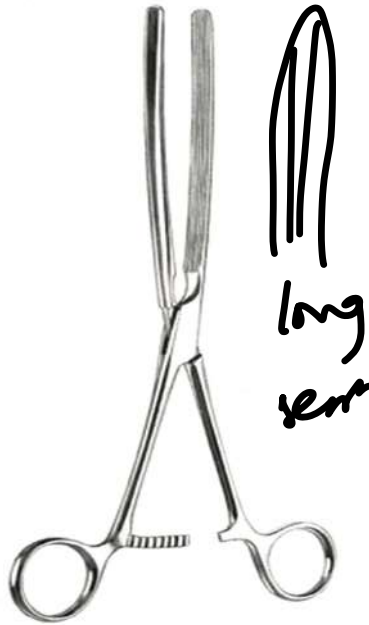
- ureter

- LN  
==

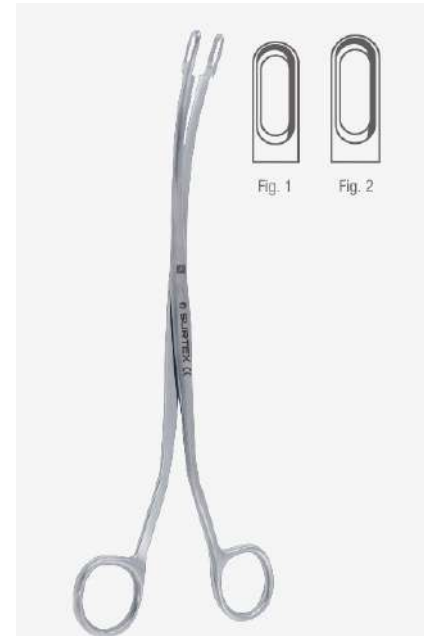
- round lig



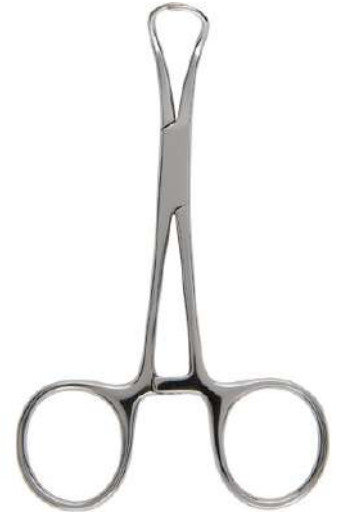Sampson's  
sponge holding  
forceps



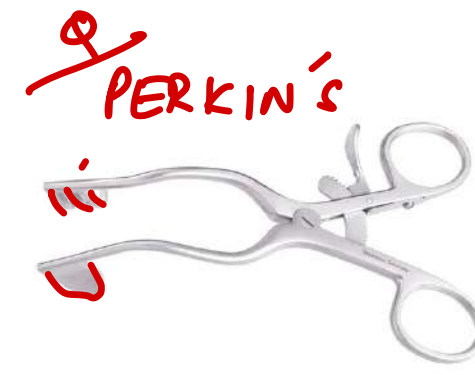
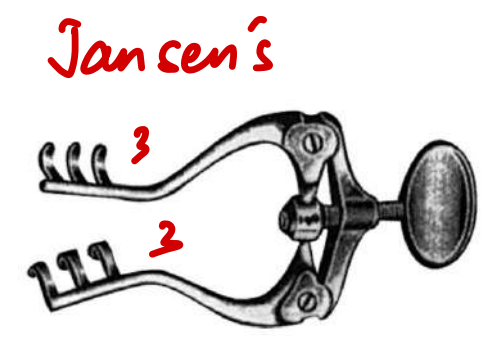
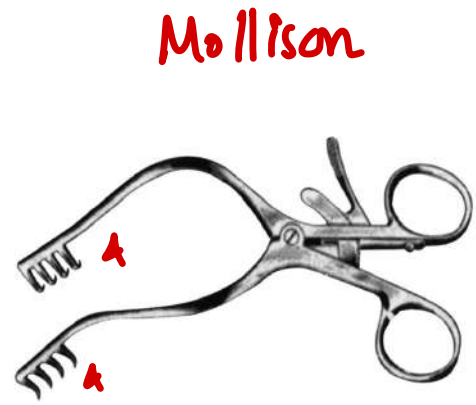
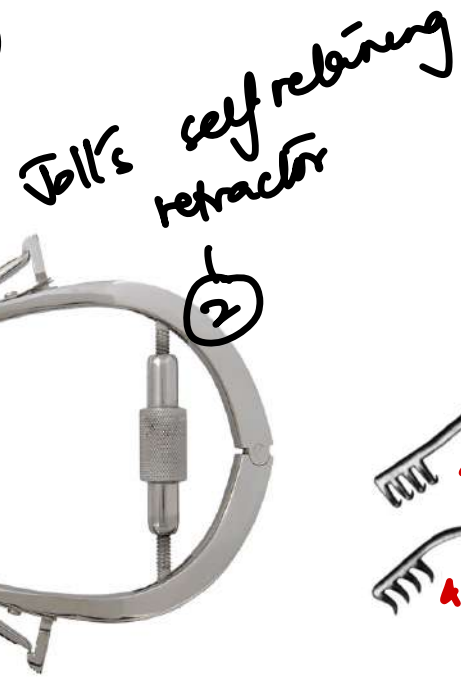
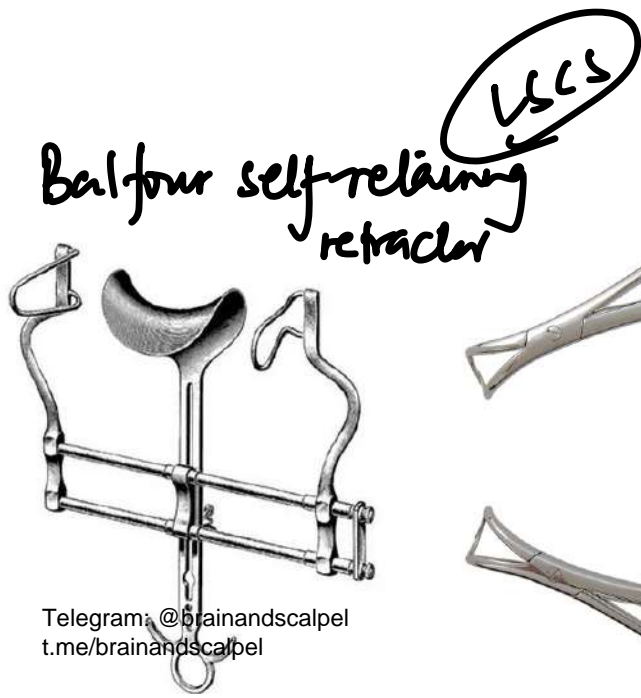
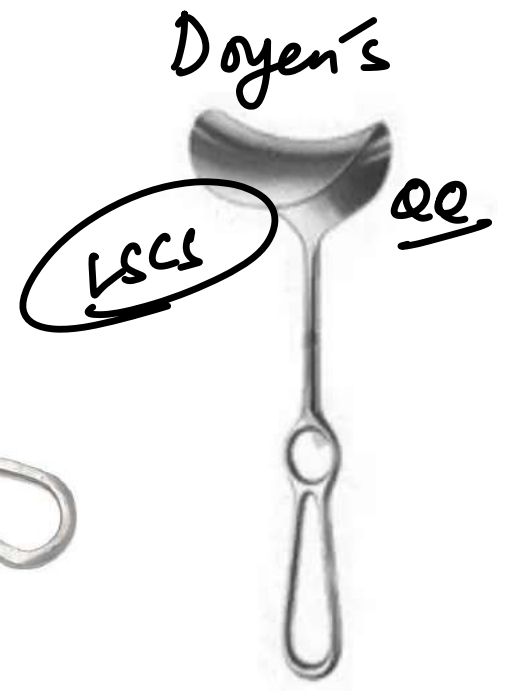


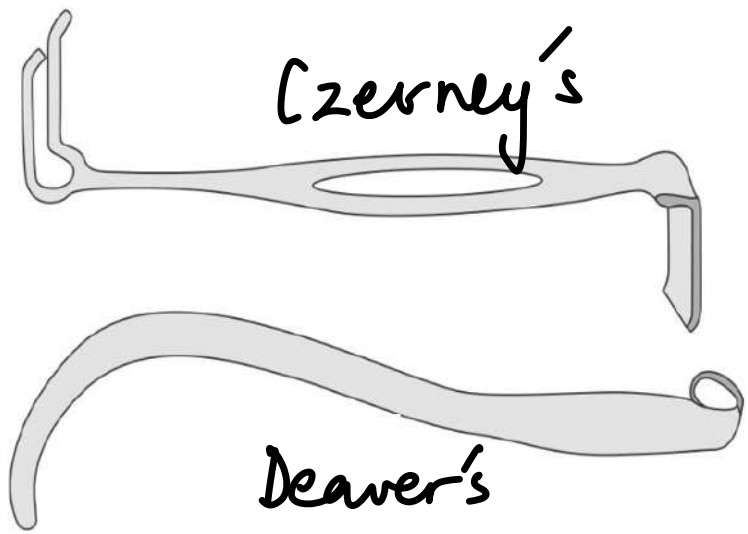
intestine  
clamp  
(↓ traumatic)

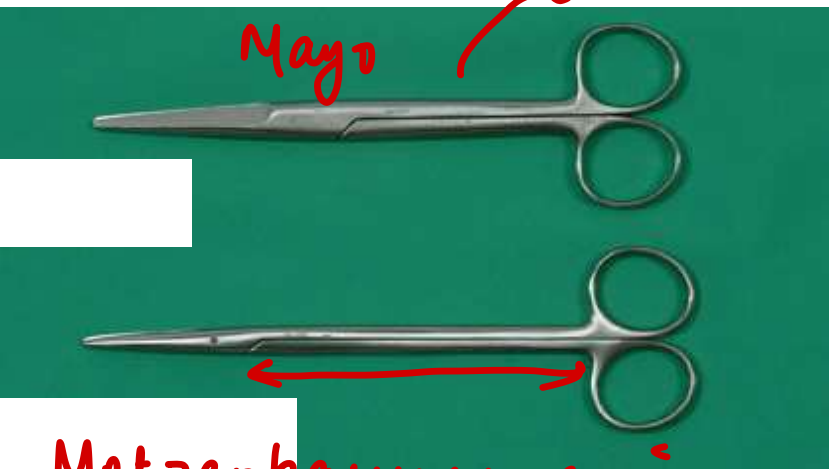


Desjardine's  
↓  
open CBD  
explor  
(choledocholithotomy)



Mayo's  
towel  
clip






short & stout → aponeurosis ligaments



criss-cross

↓

Needle holding forceps



Adson's tissue holding forceps ✓



skin muscle


↓ stab, I & D

↓ suture removal } precise  
↓ }  
pedic, minor OT

Metzenbaum scissor

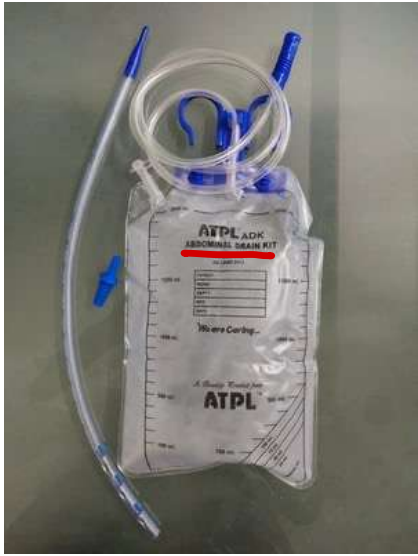↓

VB tubectomy genitrium ✓

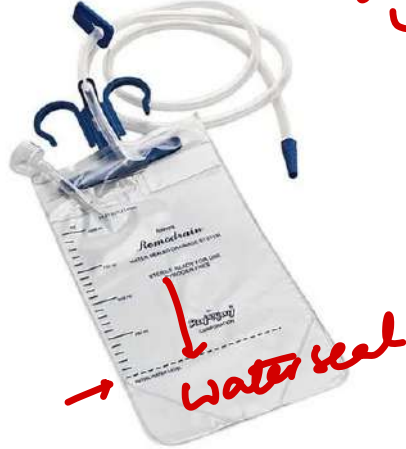

B-P handle

abdo drain bag



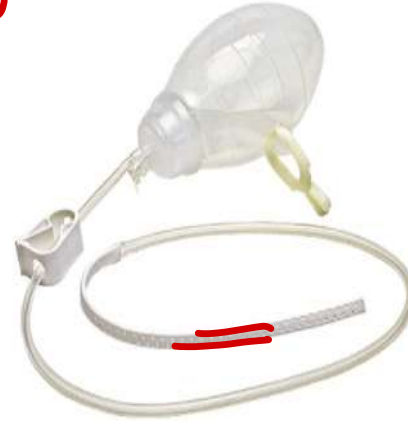chest tube drainage bag




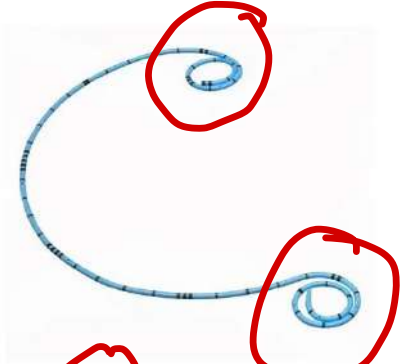
Romana c drain (closed)




Jackson Pratt Labdo



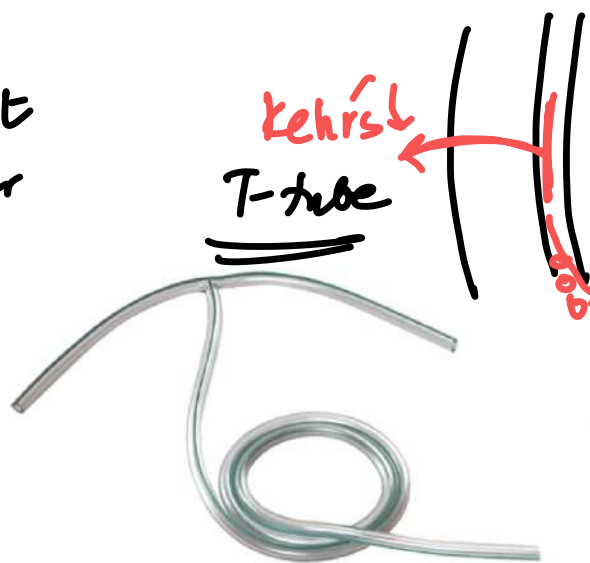
DJ stent Luvetic



thick / SPC - Malecot catheter



kehrst T-tube

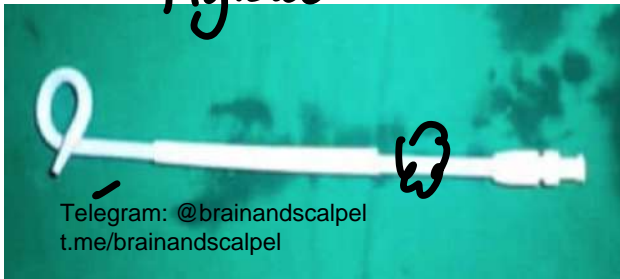

red rubber catheter



Flatus tube

Pigtail - abscess






Verres needle

• 45° • CO<sub>2</sub>: 20mm Hg

• bevelled edge

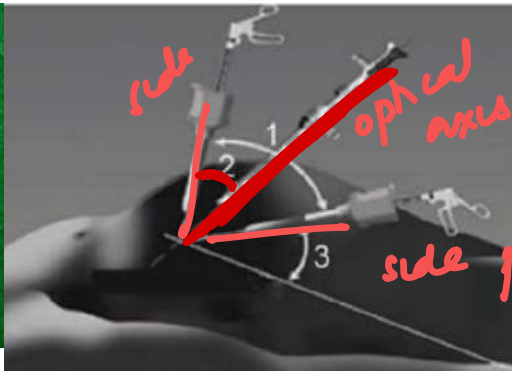
↳ r/o organ injury

• Confine → saline → ⊗ respiration



Trocar-Cannula


↳ Laparoscope



1- manipulator  $\angle \rightarrow 60^\circ$

2- Azimuth  $\angle \rightarrow 30^\circ$

3- Elevator  $\angle \rightarrow 30^\circ$



Harmonic Scalpel

↳ ultrasonic waves

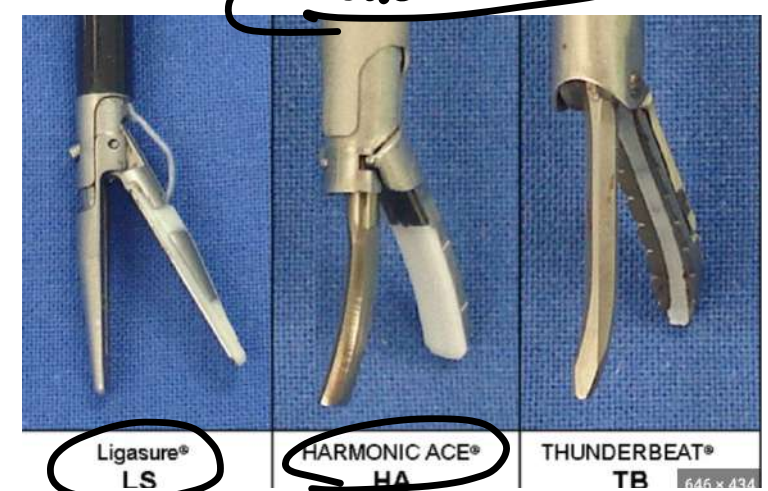
seal

Cut

Gases:  
Co<sub>2</sub> - MC  $\left\{ \begin{array}{l} \times \text{ combustible} \\ \text{soluble} \end{array} \right.$   
 ↳ r/o hypercapnia - COPD

N<sub>2</sub>O - analgesia (⊖) - combustible  
Helium - COPD (⊖) - expensive  
Room air

Vessel sealer



Ligasure® LS


HARMONIC ACE® HA

THUNDERBEAT® TB


↳ Δ/pressure

↳ harmonics


↳ Both



CUSA



Monopolar cautery



Bipolar cautery




Linear stapler  
Res & anast



Circular  
Hemorrhoid

(x NS)  
glycine 10w



Intax

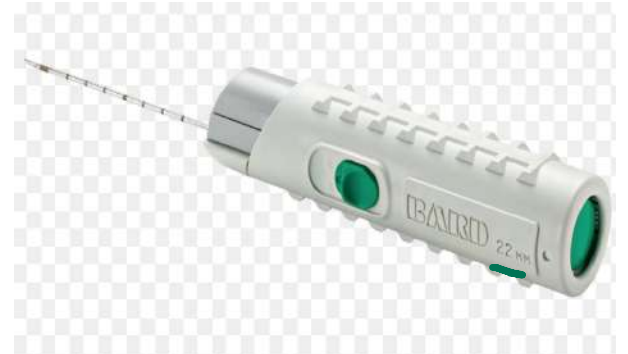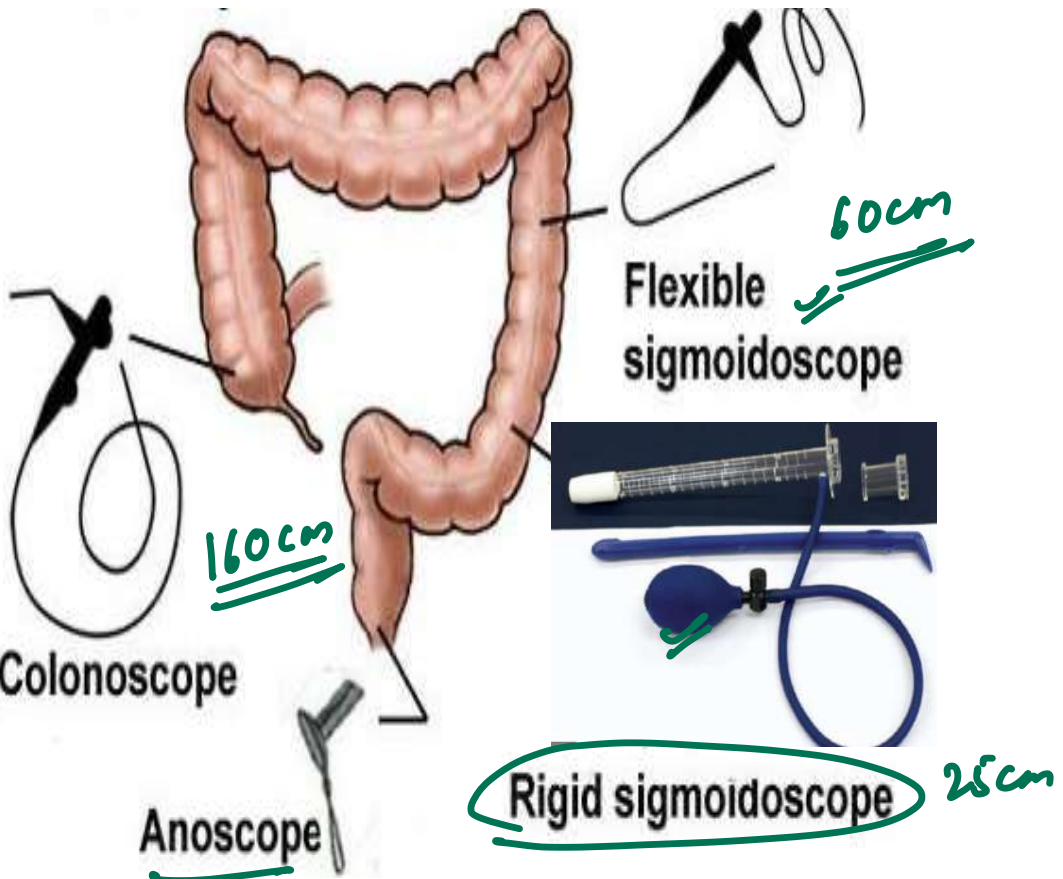S-B tube

Minnesota

OGIB

temporade

PPH



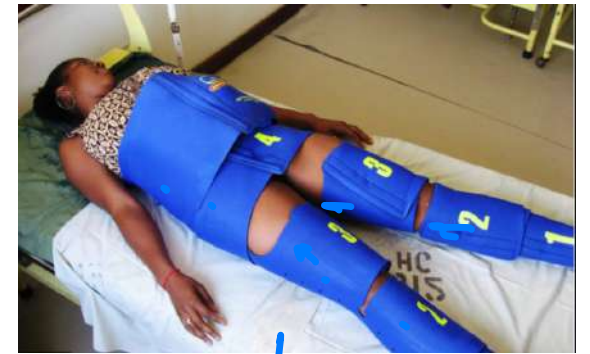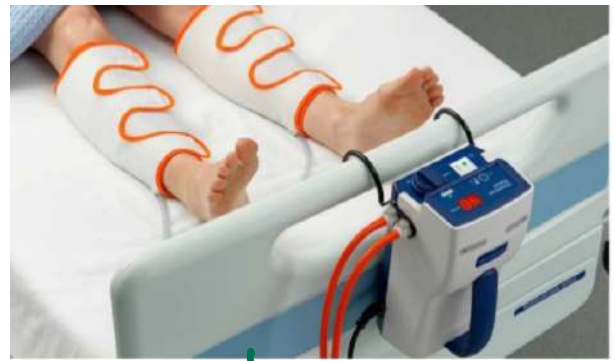2.2mm breast

14G-16G

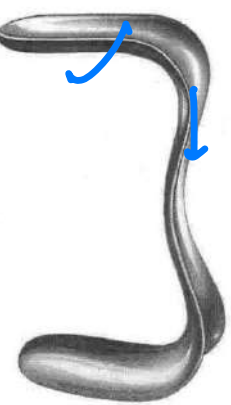
Kelly's proctoscope



VGIE → 120cm



# OBG



Sim's speculum




Cusco's self-retaining speculum



Anvard's self-retaining weighted speculum



Sim's Ant vag wall chade



Vulsellum



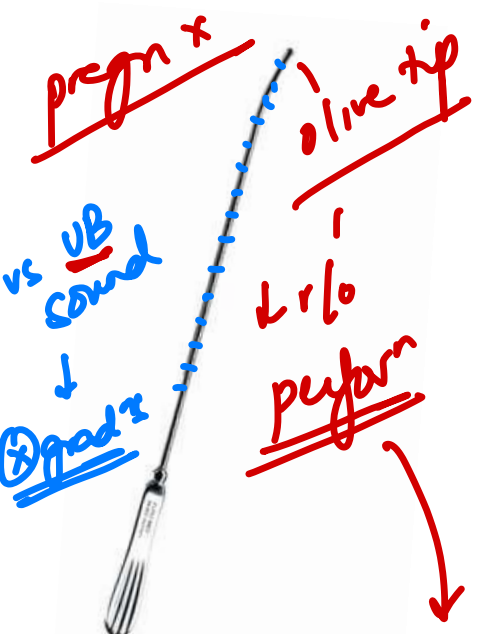
Sponge

☹️ - ❌ see walls

. CuT / Pap smear

- ✓ vag hyster
- ✓ VVF repair

Nulliparous- Tenaculum - <sup>one</sup> tooth  
 Pregnancy- sponge holding  
 Posterior lip- POD / cervical tears



Uterine sound  
UCL / angul<sup>n</sup>  
↓  
(N) - 6-8 cm

conservative Mx  
• wait & watch



Hegar's dilators

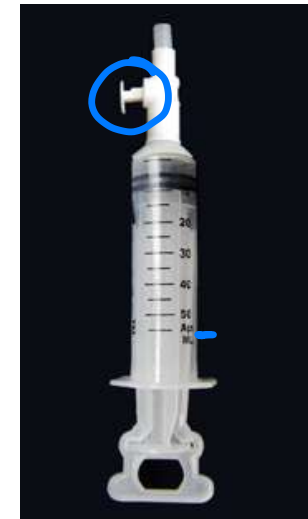↓  
• POG - 1  
• cervical incompetence  
  in non pregnant  
  ( no. 8 dilator )  
↓  
nonpregn cerclage: Lash & Lash



Hawkin ambu dilator



PHC / remote  
MVA - 60ml = POG / POG - 1  
L 660 mm<sup>2</sup> Hg  
MTP: 12wks POG



Menstrual regul<sup>n</sup> syringe  
MTP → 6wks



Curette  
obs → blunt

Complete evacuation signs:  
1. No more products  
2. Grating sensation 3. Clipping  
4. Bubbling 5. Contract uterus



Oum forceps

> 12 wks MTP

endometrial  
biopsy

Leech-  
Wilkinson  
HSG

Rubin  
Canula  
HSG

Hulka's  
uterine  
manipulator



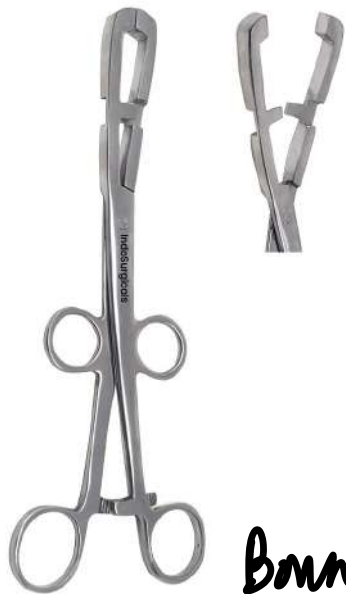Hysteroscope

PMB - ET > 4mm  
post menop (tamoxifen) ET > 8mm

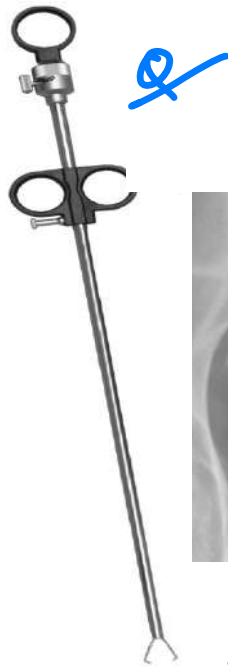Perimenop - ET > 12mm




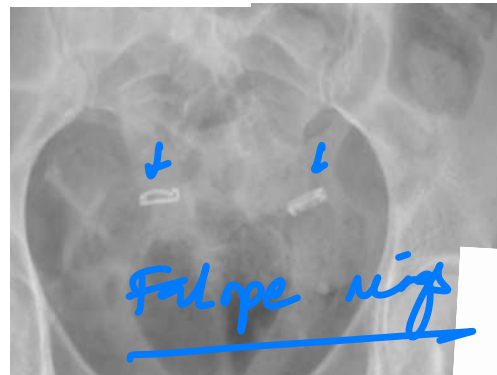
Doyen's myoma  
screw



Bouney's  
Myomectomy  
Clamp




Ring applicator



Ayre's  
12  
extos

LBC (1sa)  
cytobrush



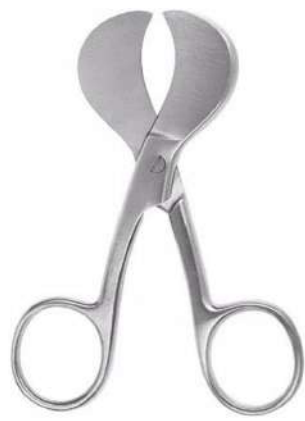95%  
chandel  
Pap smear

Reduce blood loss during myomectomy:  
 • GnRH analogue - x 3max prep  
 • Vasopressin / TXA intraop  
 • Hypotensive anaesthesia . Clamp

Order of clamp-cut-ligate during hysterectomy:  
 1. Round lig  
 2. ovarian lig  
 3. FT → BSO -  
 4. Broad lig  
 5. uterine A - uterine  
 6. Cardinal lig  
 7. uterosac lig  
 Infundibulopelvic lig



Episiotomy  
scissors




Cord cutting  
scissors



Cord clamp


3-4cm from cord.

Episiotomy  
Angle:  $60^\circ$  ML  
Timing: crowning   
Order: Mucosa  $\rightarrow$  Muscle  $\rightarrow$  Skin  
Type of perineal tear:  $2^\circ$   
Suture: Vicryl / chronic catgut  
Muscles cut: Bulbospongiosus, Levator ani, Superficial and deep transverse perinii

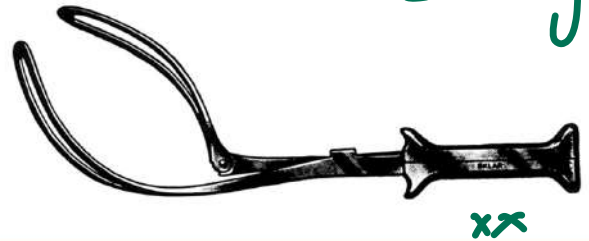Not cut: Ischio cavernosus / coccygeus, obturator



Wigley's outlet



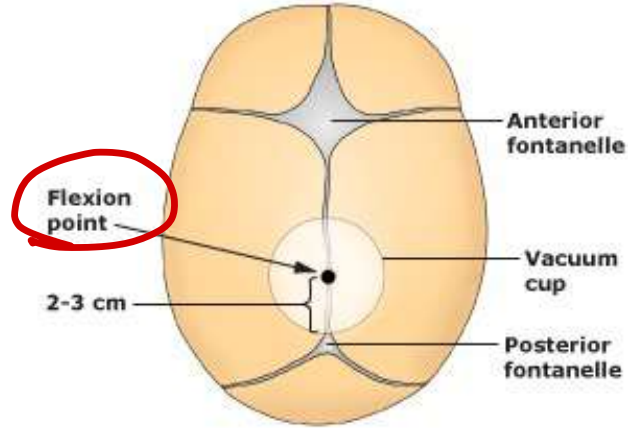
→ Kielland rotational forceps  
sliding lock



Barton - OT pos<sup>n</sup>



Piper - after crowning head in breech



Vacuum Cup

Correct application:

Lt → Lt hand → Rt

Lock

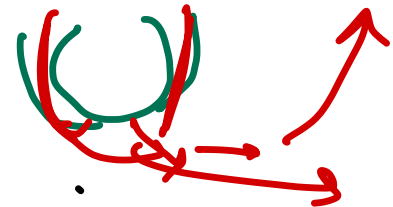
claw-back → straight → upward

Maternal or fetal distress in 2<sup>nd</sup> stage


Station >+2

No CPD

Full dilation, ruptured membranes



traction  
Curve of Cup

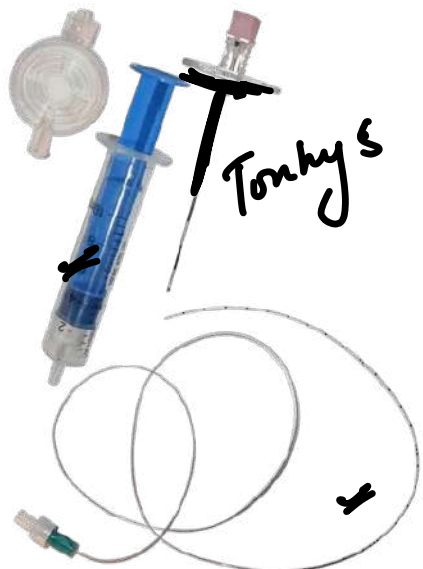

# ANESTHESIA

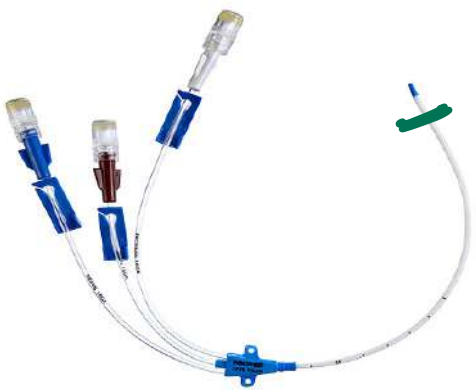
---



Spinal needle



Epidural catheter set

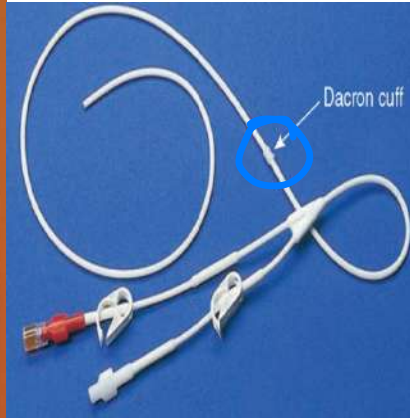

Central line

MC - IJV  
PICC - mc  
subclavian



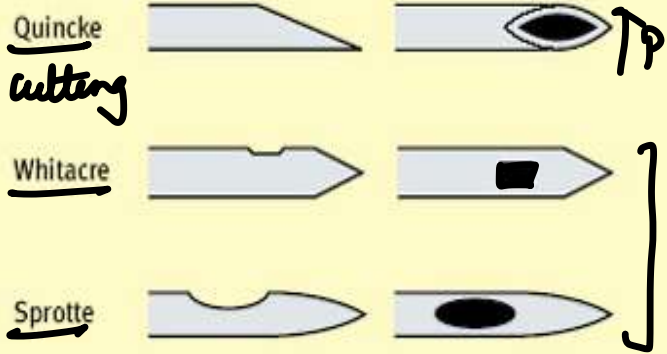
Chemoport



Tunneled catheter

Permacath  
Hickmann

PICC peripheral inserted central line

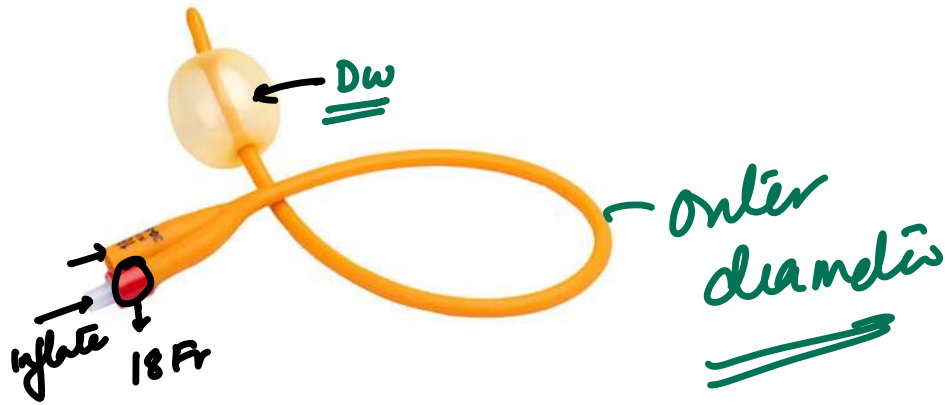


TPDPH  
dura splitting

10G → tip cutline  
brush cytology  
central line / peripheral line  
52P



iv cannula




NG tube

- Fowlers
- NEX
- NEMU

1Fr = 0.3mm

| Colour Code  | ml/min |
|--------------|--------|
| Orange - 14G | - 270  |
| Gray - 16G   | - 210  |
| White - 17G  | - 130  |
| Green - 18G  | - 80   |
| Pink - 20G   | - 50   |
| Blue - 22G   | - 30   |
| Yellow - 24G | - 20   |
| Violet - 26G | - 10   |

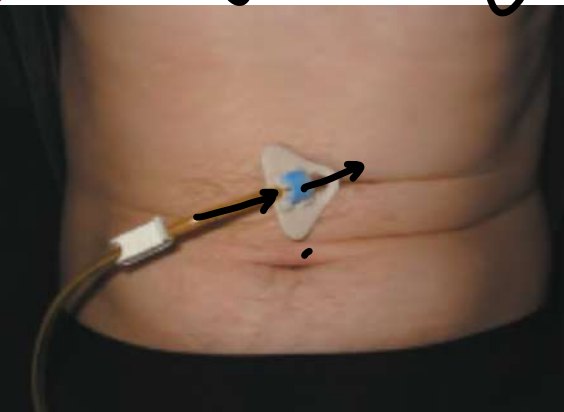
Inflation using: Dw  
 Stuck Foley's: VSA guided puncture



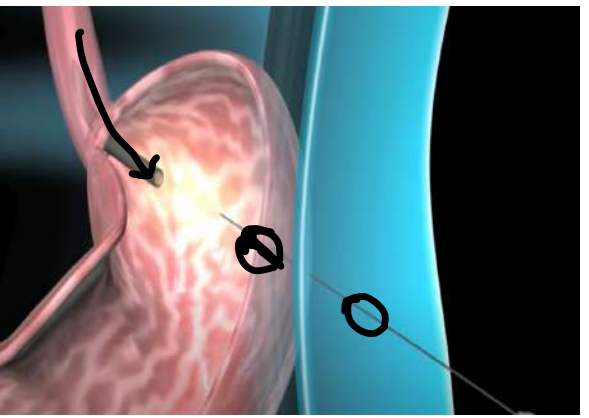
|        |      |
|--------|------|
| Green  | 14fr |
| Orange | 16Fr |
| Red    | 18Fr |
| Yellow | 20Fr |
| Purple | 22Fr |
| Blue   | 24Fr |

CI → Base of skull #

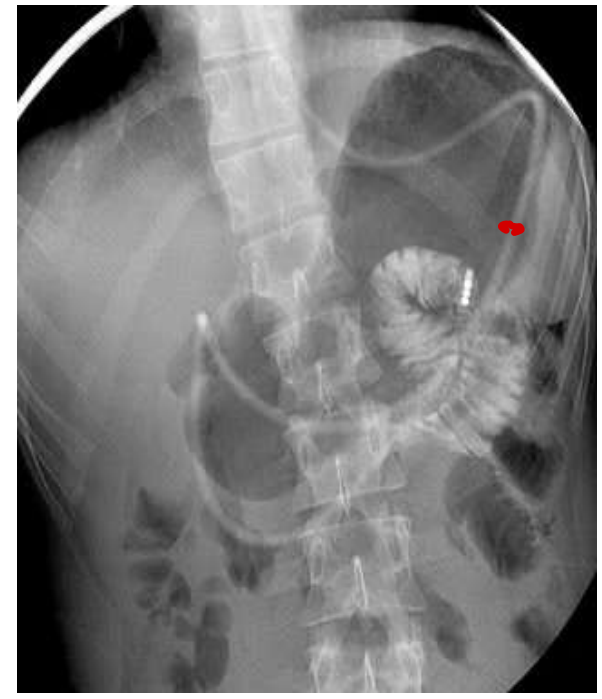PEG Percutaneous endoscopic gastrostomy

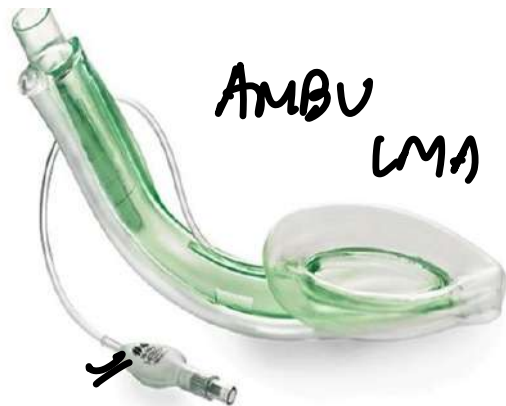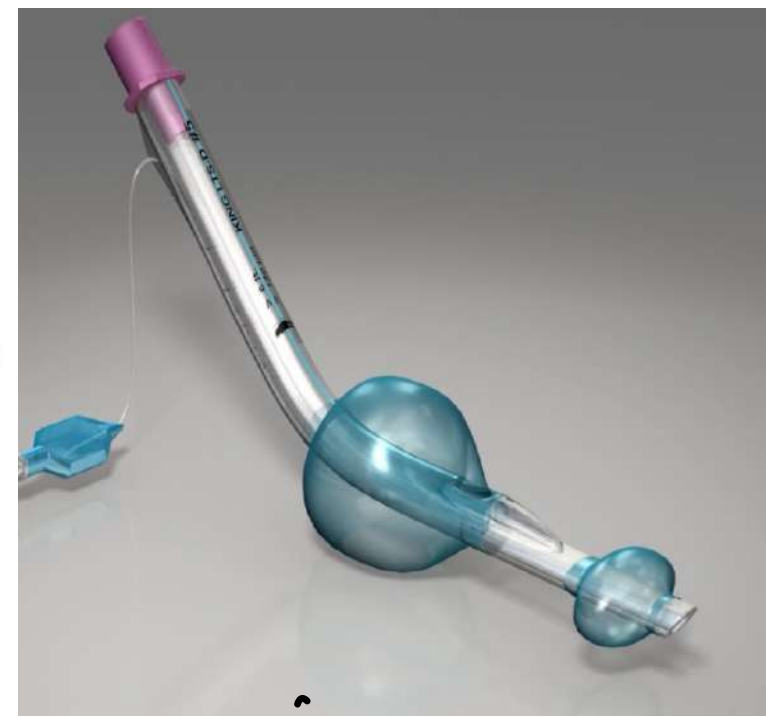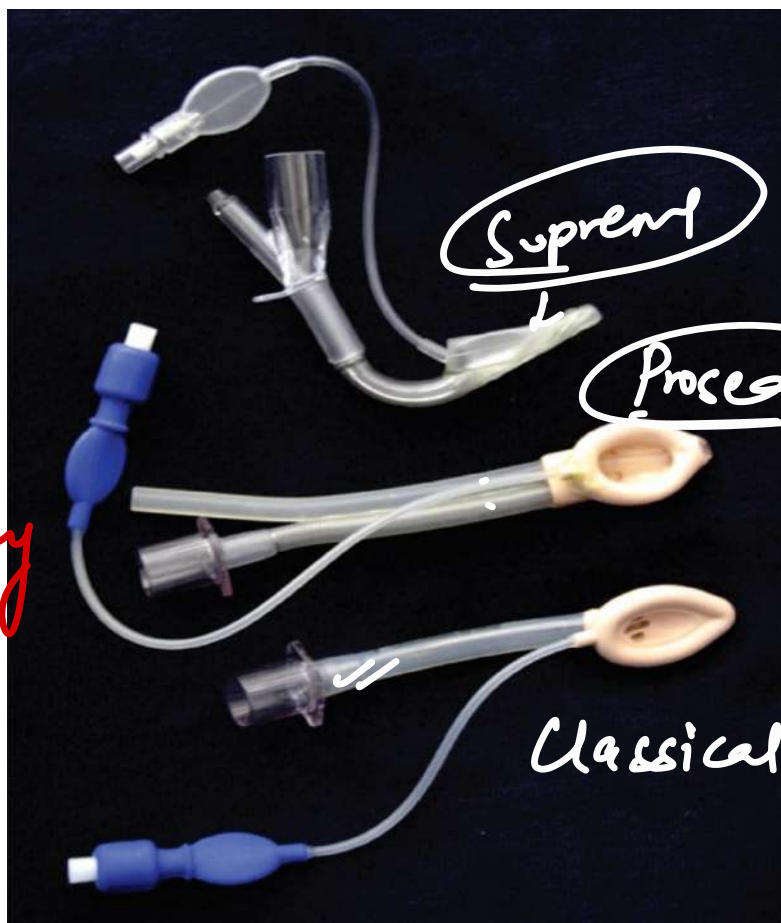


prolonged feeding



NJ tube - Feckka's tube






Mc Intosh - adult



Miller - children



McCoy

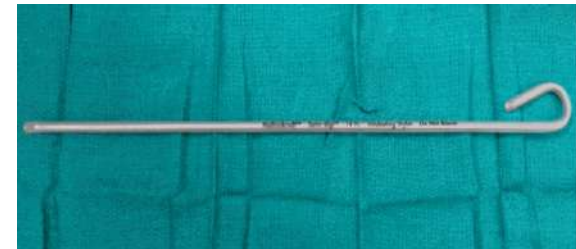

Inflate cuff with: **NC / air**  
Pressure: **< 30cm H<sub>2</sub>O**

Best → **ET CO<sub>2</sub>** **35-45mm**




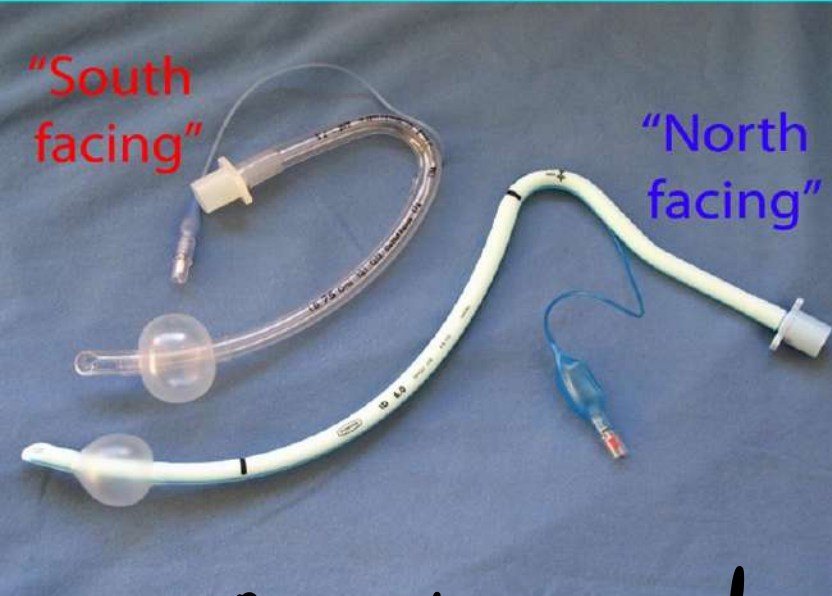
Bougie



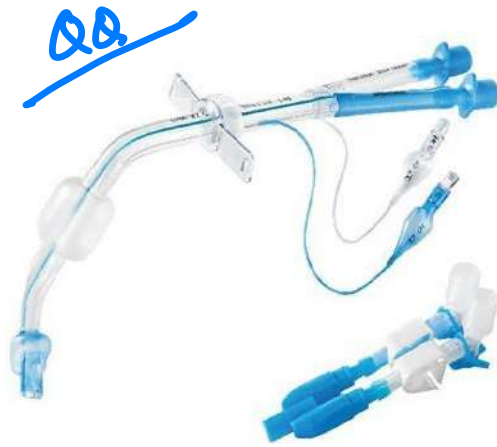stylet

# Preformed ET Tubes

South  North



RAE / preformed



Double lumen  
ET

single lung  
ventil

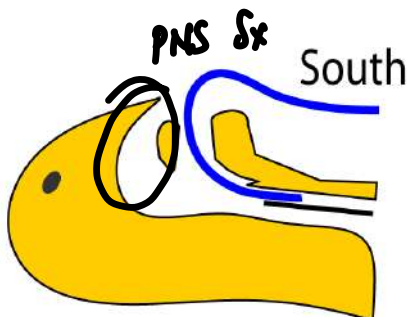
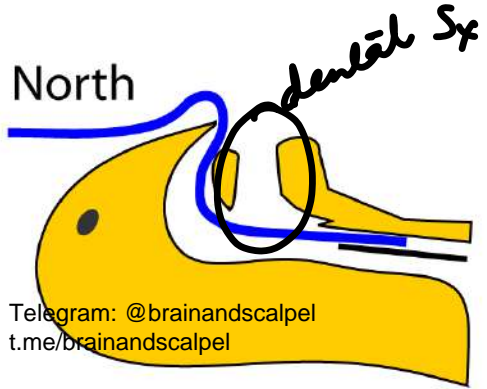


Red  
rubber tube

↓  
laser



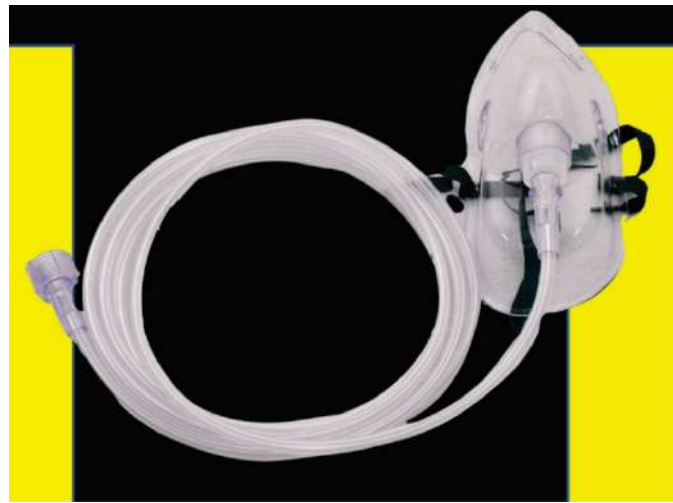↓  
Flexo-  
metallic  
tube  
prone





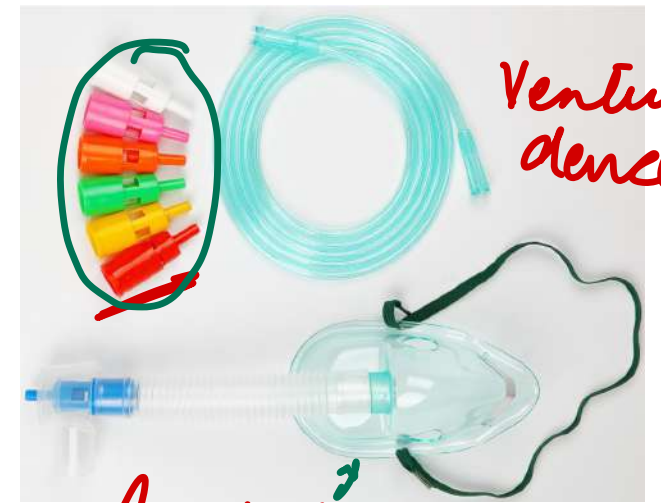Nasal prongs

5 L/min  
40%



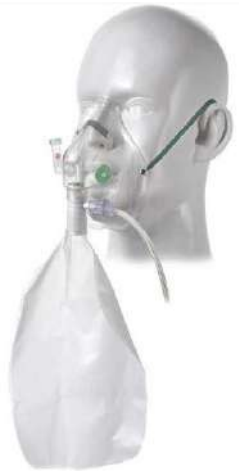Hudson mask

10  
60%



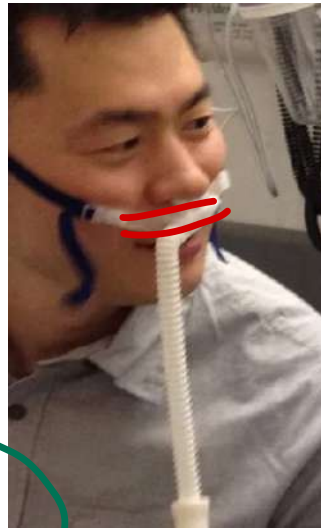
Venturi device

Fixed % O<sub>2</sub> - COPD  
15  
60%



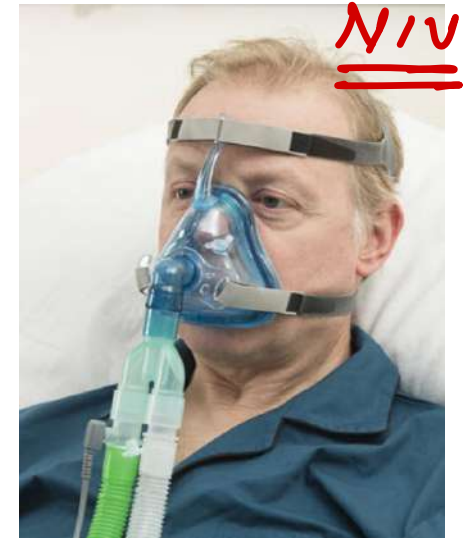NRBM

15  
85-95%



HFNC

60  
100%

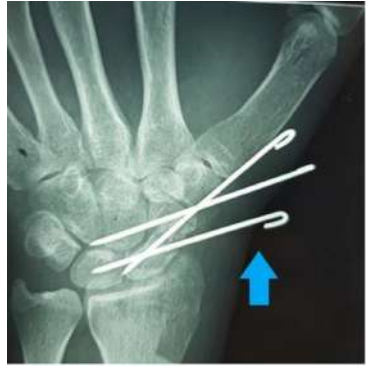
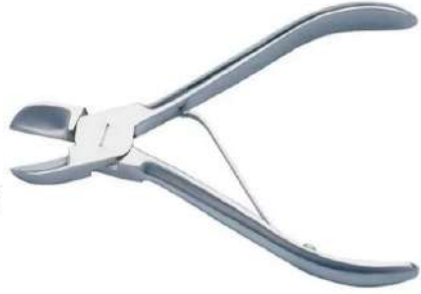
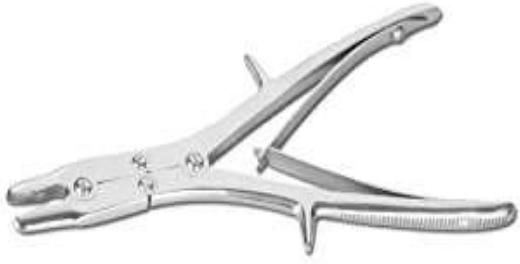NIV

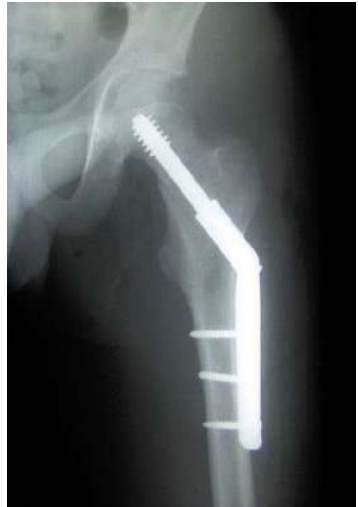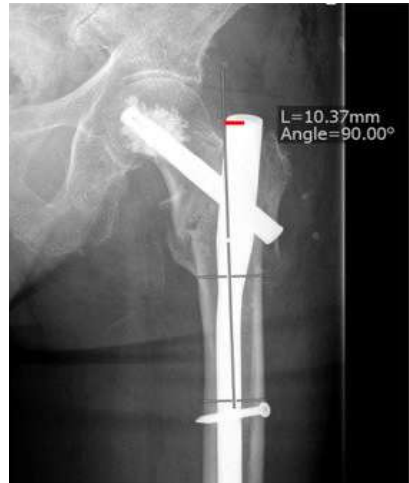

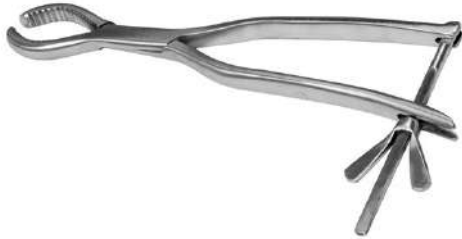∞  
100%

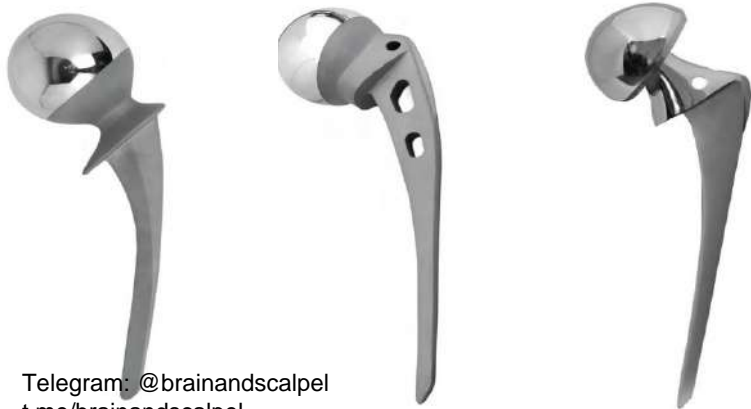
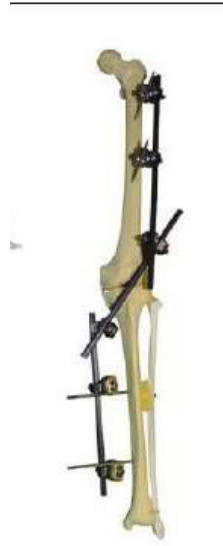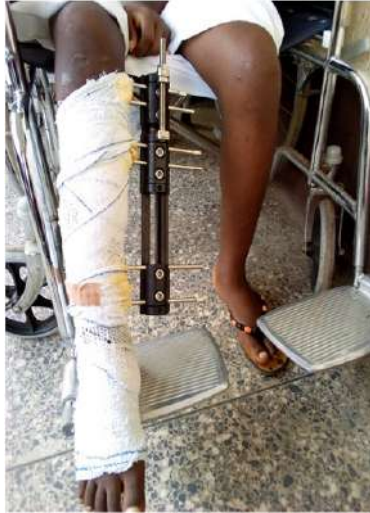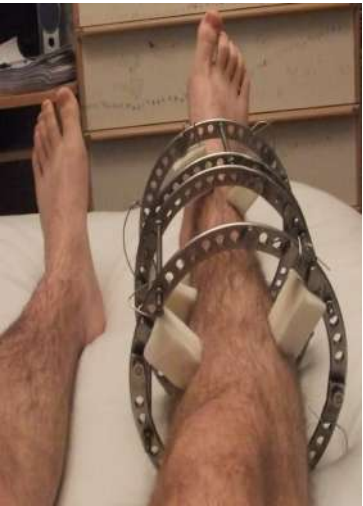# ORTHOPEDICS

---



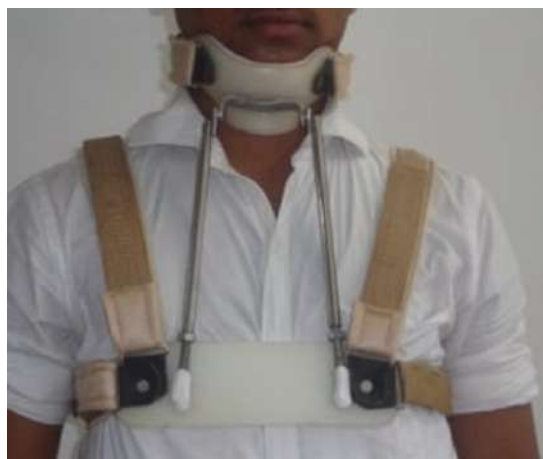Telegram: @brainandscalpel  
t.me/brainandscalpel

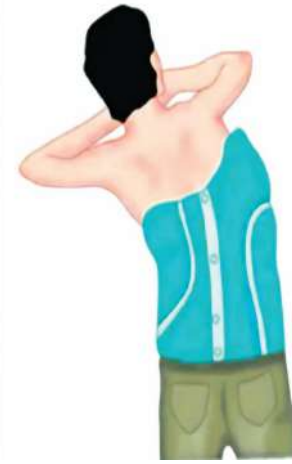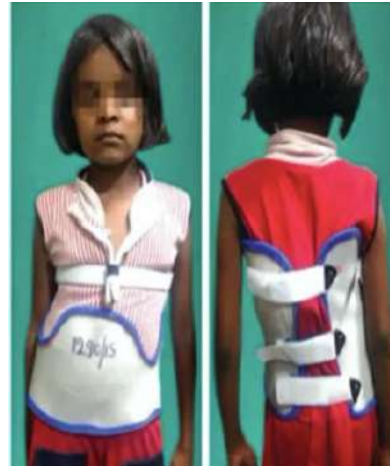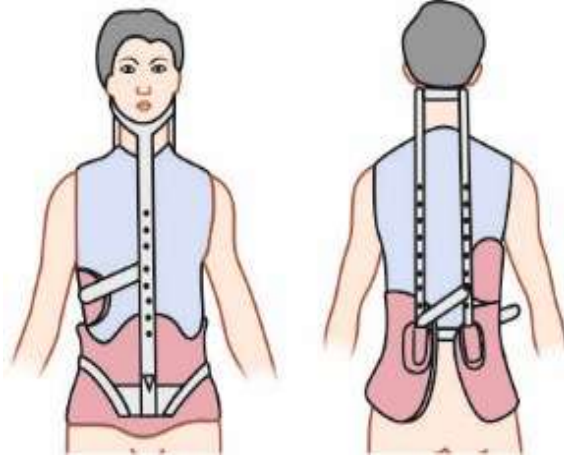
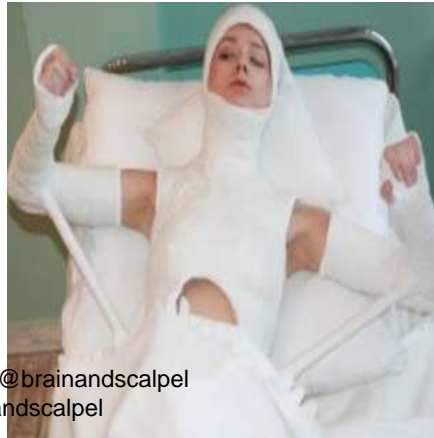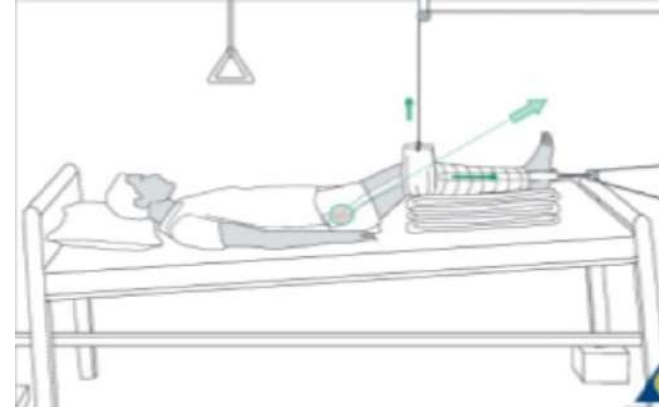
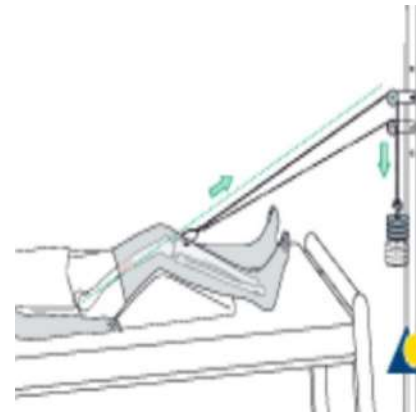
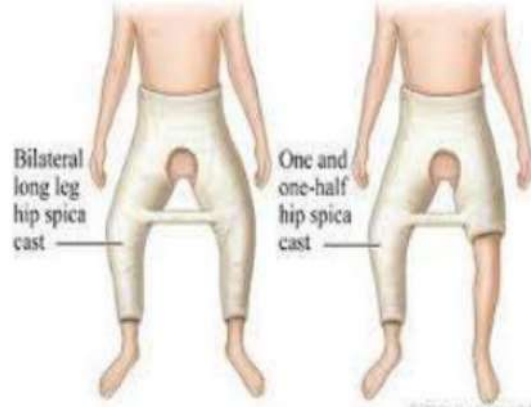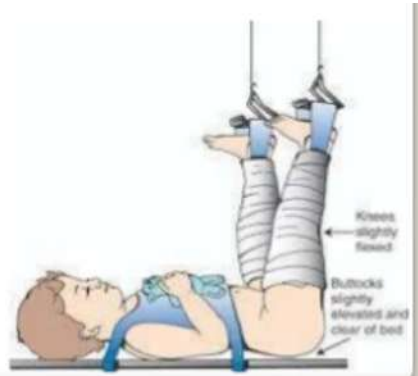


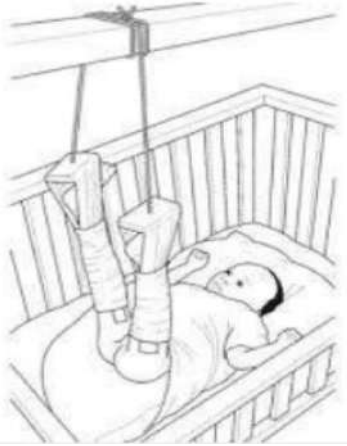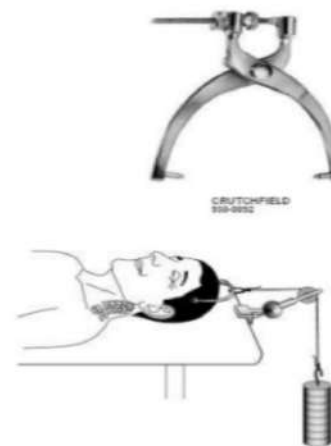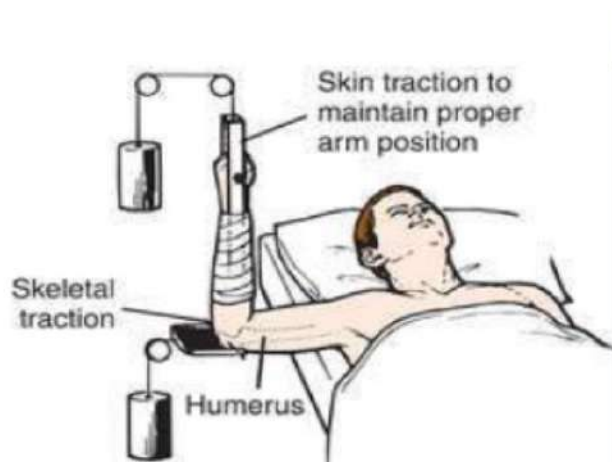


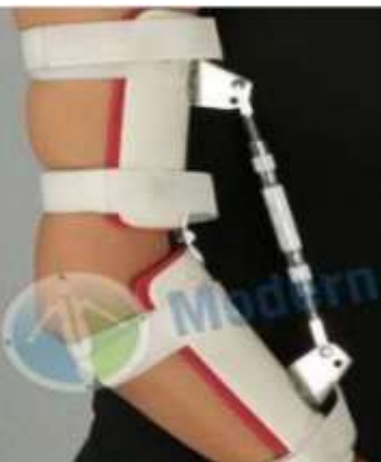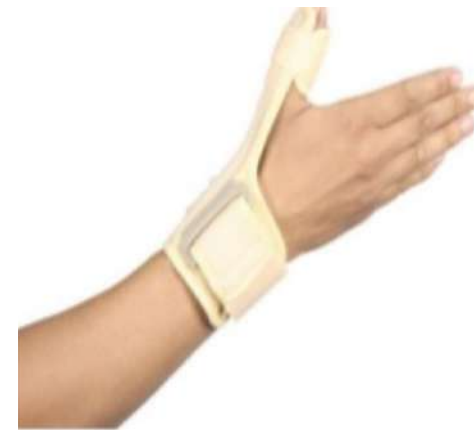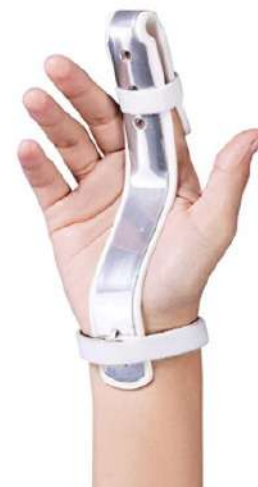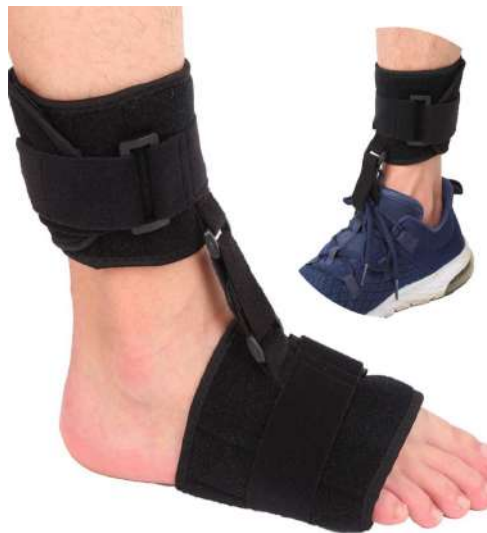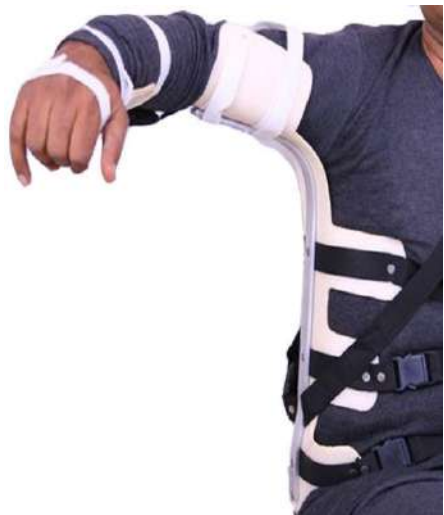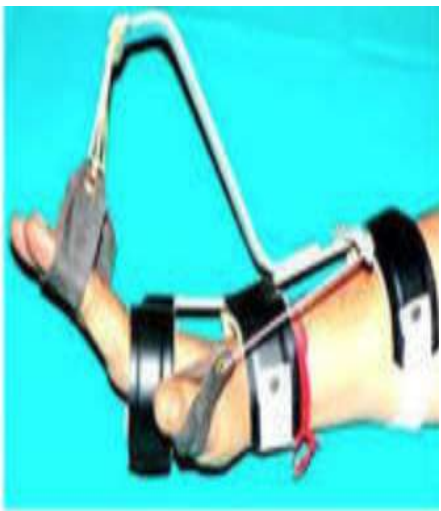Telegram: @brainandscalpel  
t.me/brainandscalpel



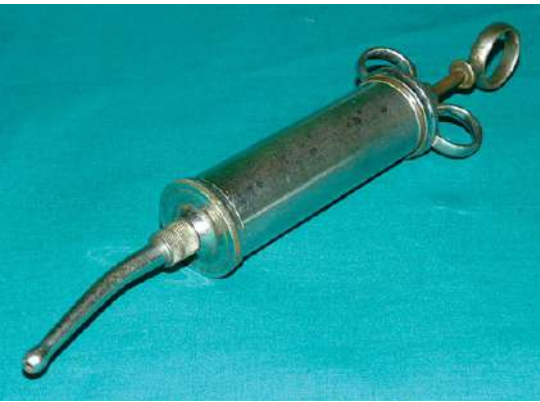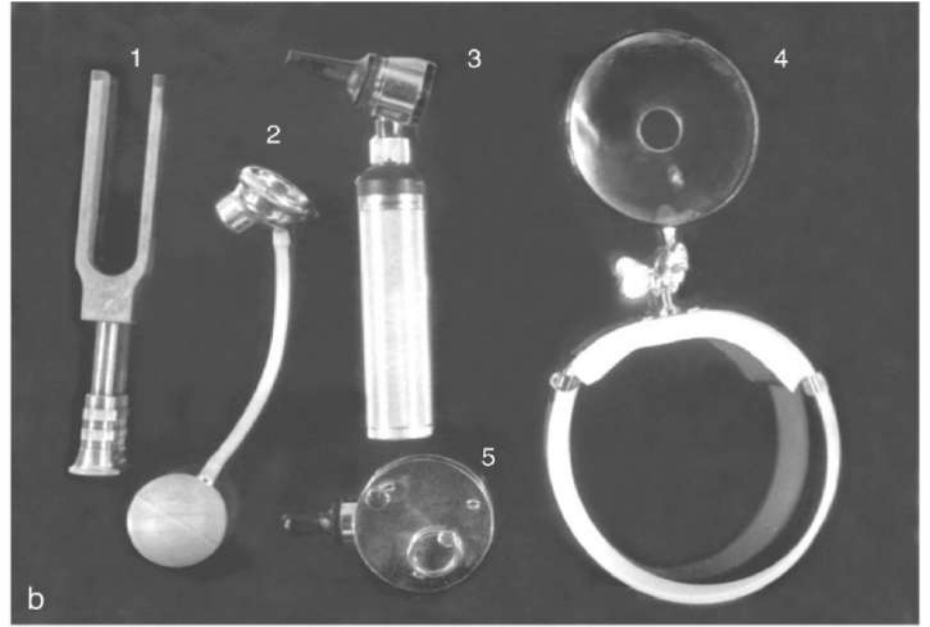




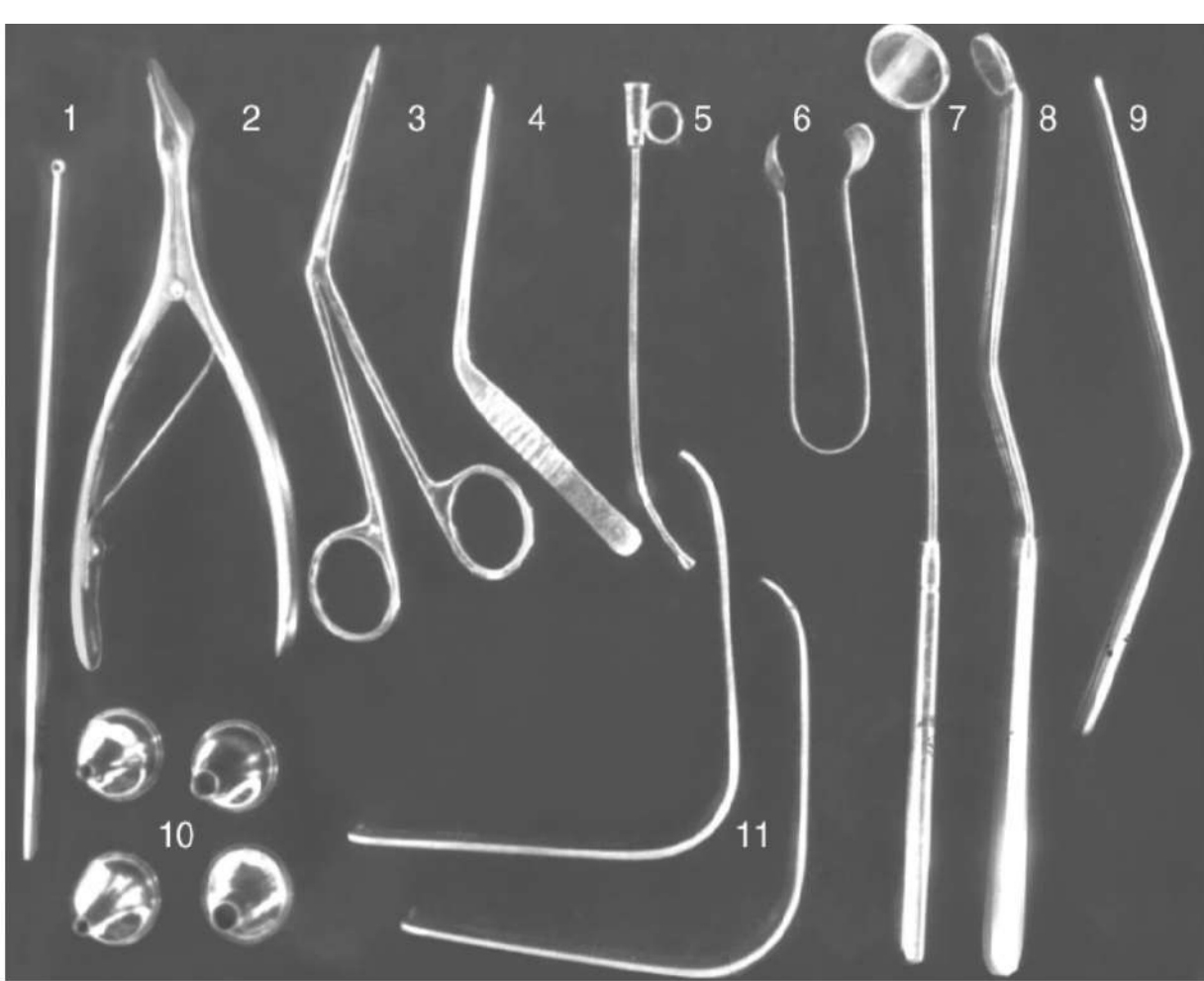

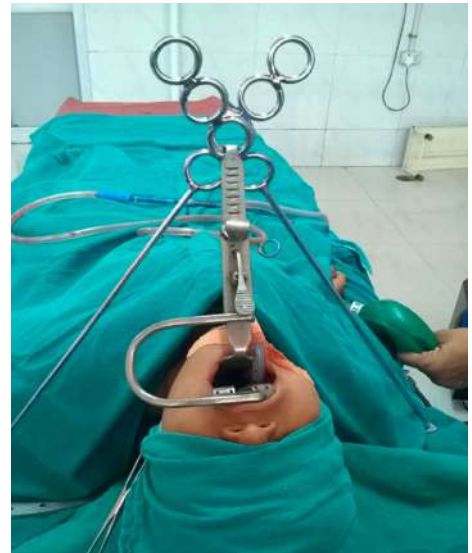
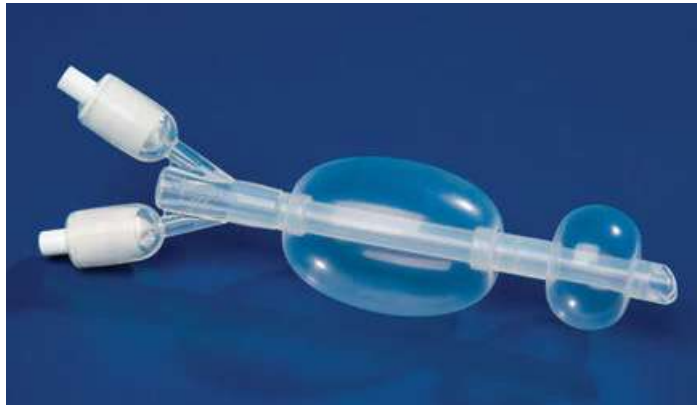
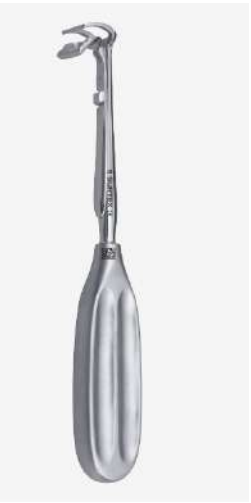
**ENT**

---

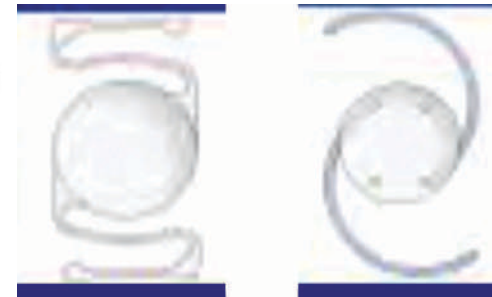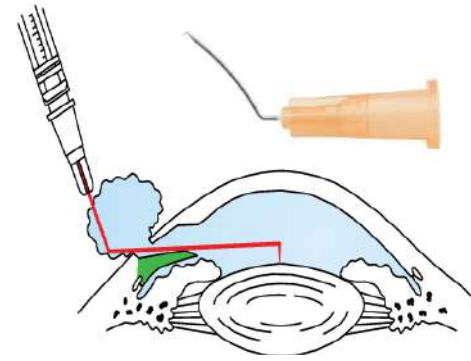



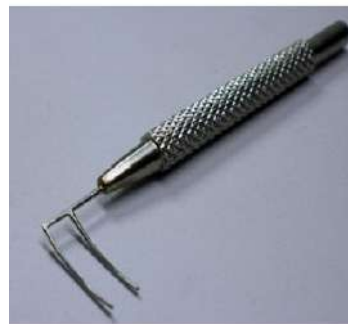


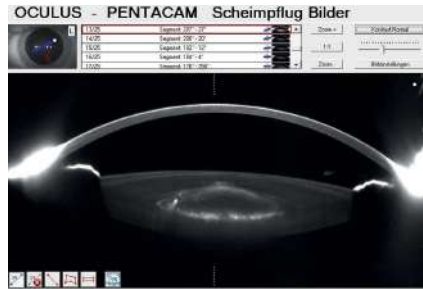
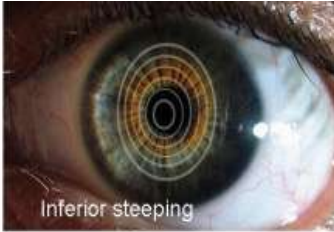
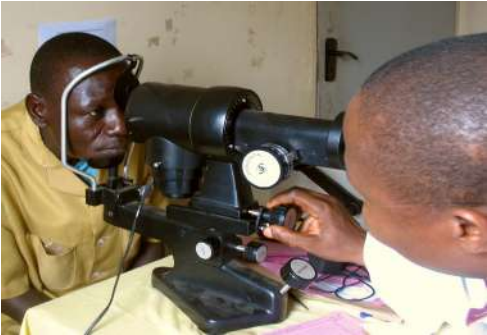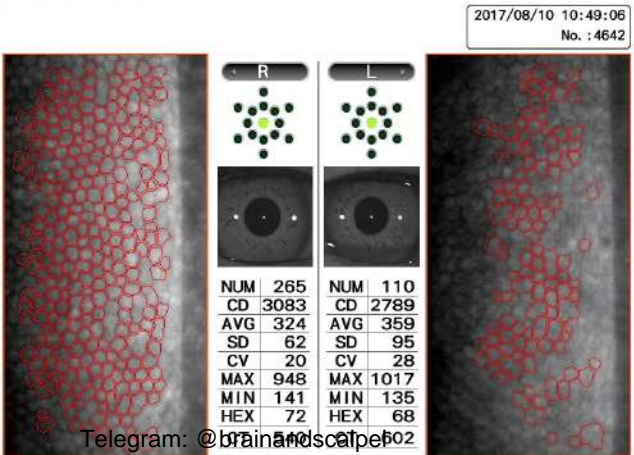
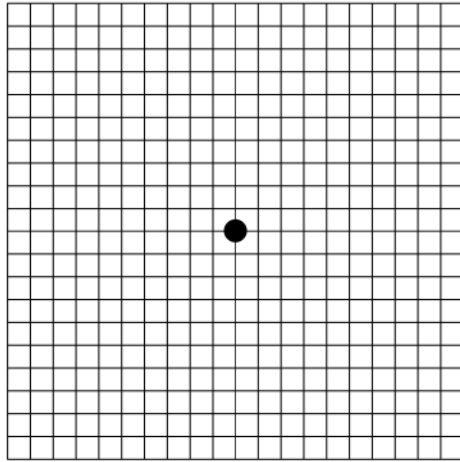
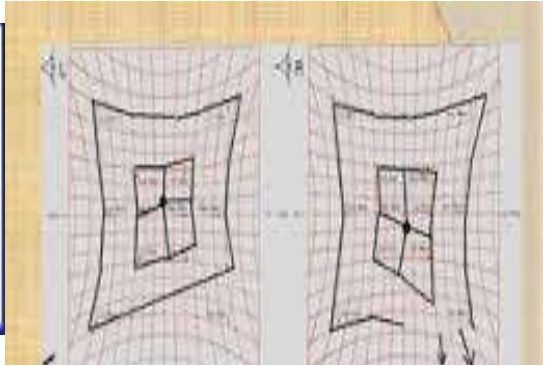

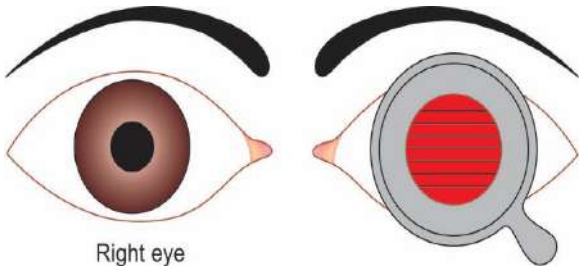


# OPHTHALMOLOGY

---





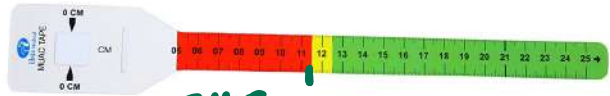




# PSM

---

Shaker tape

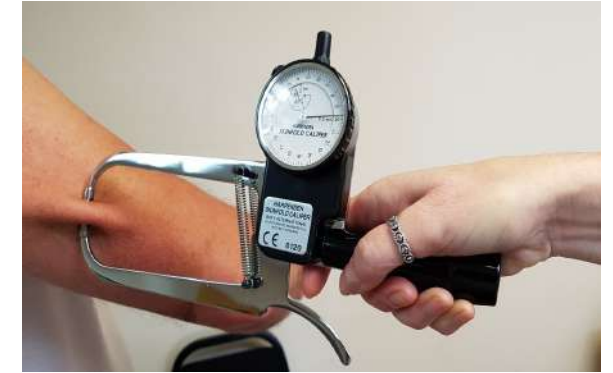

<11.5cm

MUAL



Infantometer  
<2yr



Hanging caliper

Horrock's apparatus



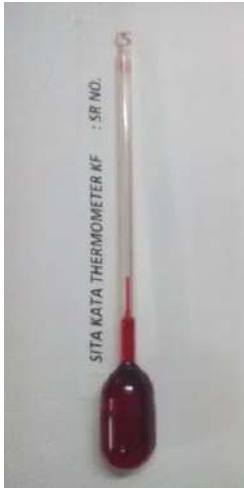Cl<sup>-</sup> demand



Residual  
Cl<sup>-</sup>  
Chloroscope



OTA  
|  
free + residual  
Cl<sup>-</sup>



Kata  
thermometer

- low air velocity

• cooling temp air



Globe

effective  
temp




Sling  
psychrometer

Humidity



Anemometer

↓  
wind vel



wind vane

↓  
dir




barometer  
↓  
pressure

→ Bonus BTR

- ortho

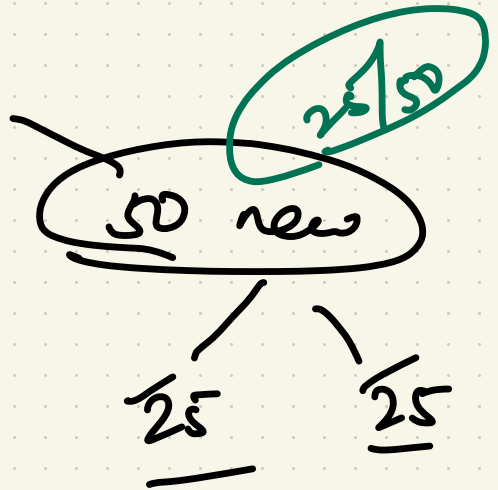

- phal

- ENT



2nd

Test



10 - INEET

Telegram: @brainandscalpe

10 - INI

5 - FM 9

mn: 70